

# Nummular Dermatitis as a Potential Adverse Effect of Dupilumab

## A Report of Two Cases

DR OLGA PAWLIK, DR MICHELLE MCRAE  
PINNACLE DERMATOLOGY, 272 ANSON STREET, ORANGE, 2800, AUSTRALIA

(EMAIL: [OLGAKPAWLIK@GMAIL.COM](mailto:OLGAKPAWLIK@GMAIL.COM))

THE AUTHORS HAVE NO CONFLICTS OF INTEREST TO DECLARE

# Introduction

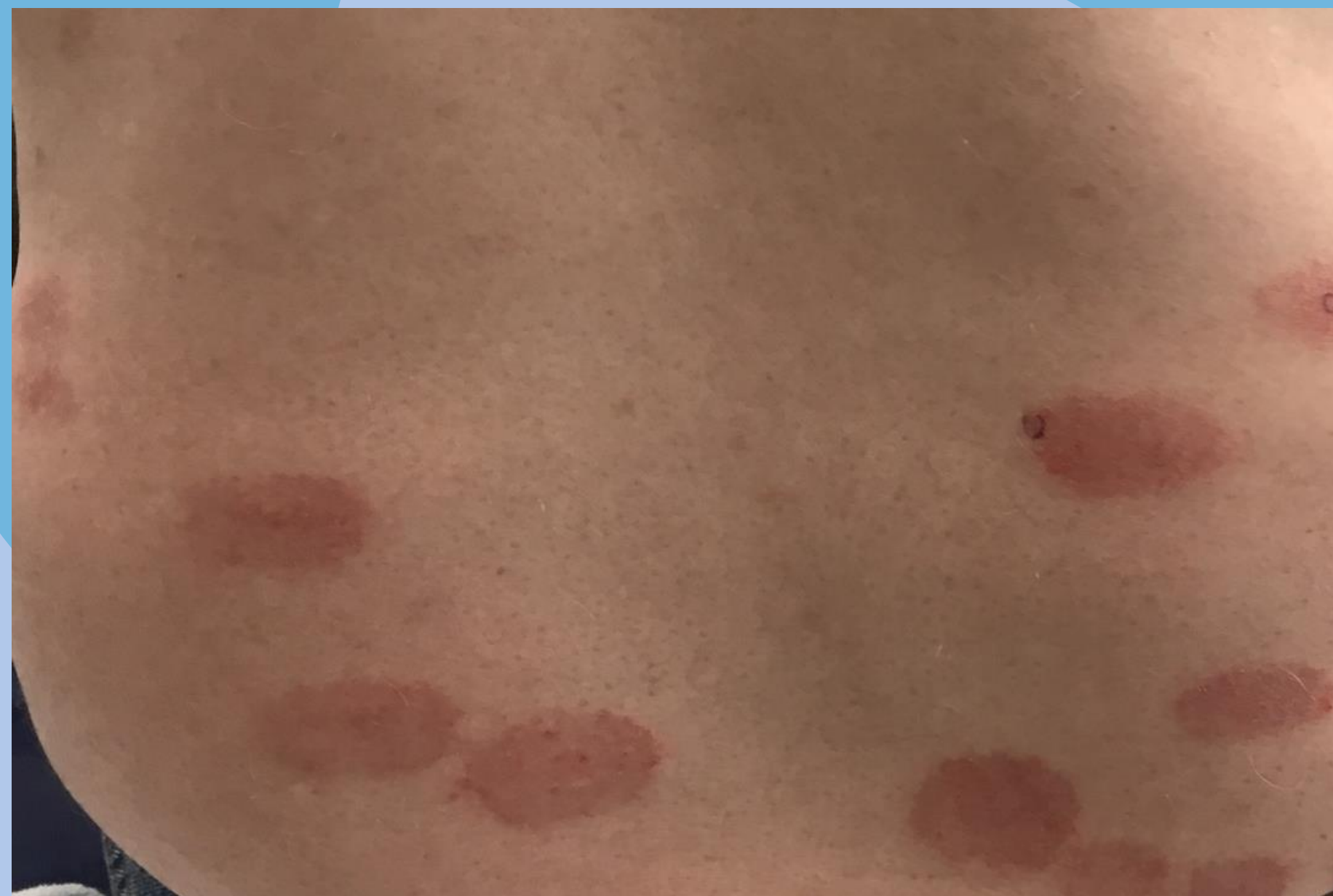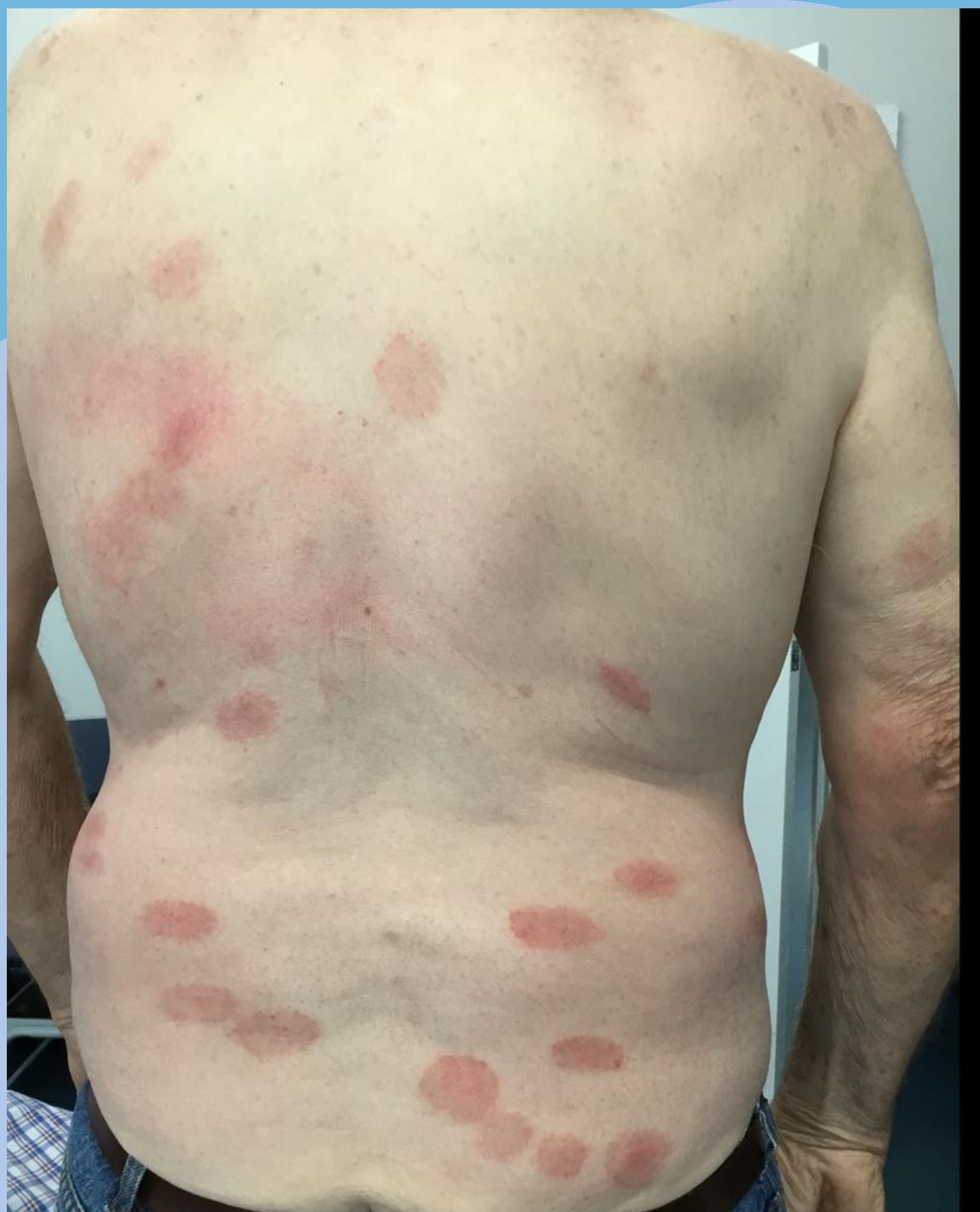- Nummular dermatitis (discoid eczema) is considered a variant of eczema, which shares some histologic features with psoriasis. (1)
- We present two patients who developed nummular dermatitis for the first time after the initiation of dupilumab.

# Patient A

- 34-year-old woman
- Childhood onset atopic dermatitis
  - Affecting eyelids, flexures, and abdomen
- Near total resolution on dupilumab
- Within 5 months developed intensely itchy, well-defined plaques on the upper arm, axilla, and anterior thigh, consistent with nummular dermatitis
- Plaques require ongoing topical corticosteroids

# Patient B

- 70-year-old man
- Longstanding atopic dermatitis
  - Baseline EASI 25.2; DLQI 18
- History of bullous pemphigoid and SJS
- Excellent response to dupilumab
- Within 4 months, he developed intensely itchy discoid lesions on his flanks and lower back
- Histology confirmed nummular eczema



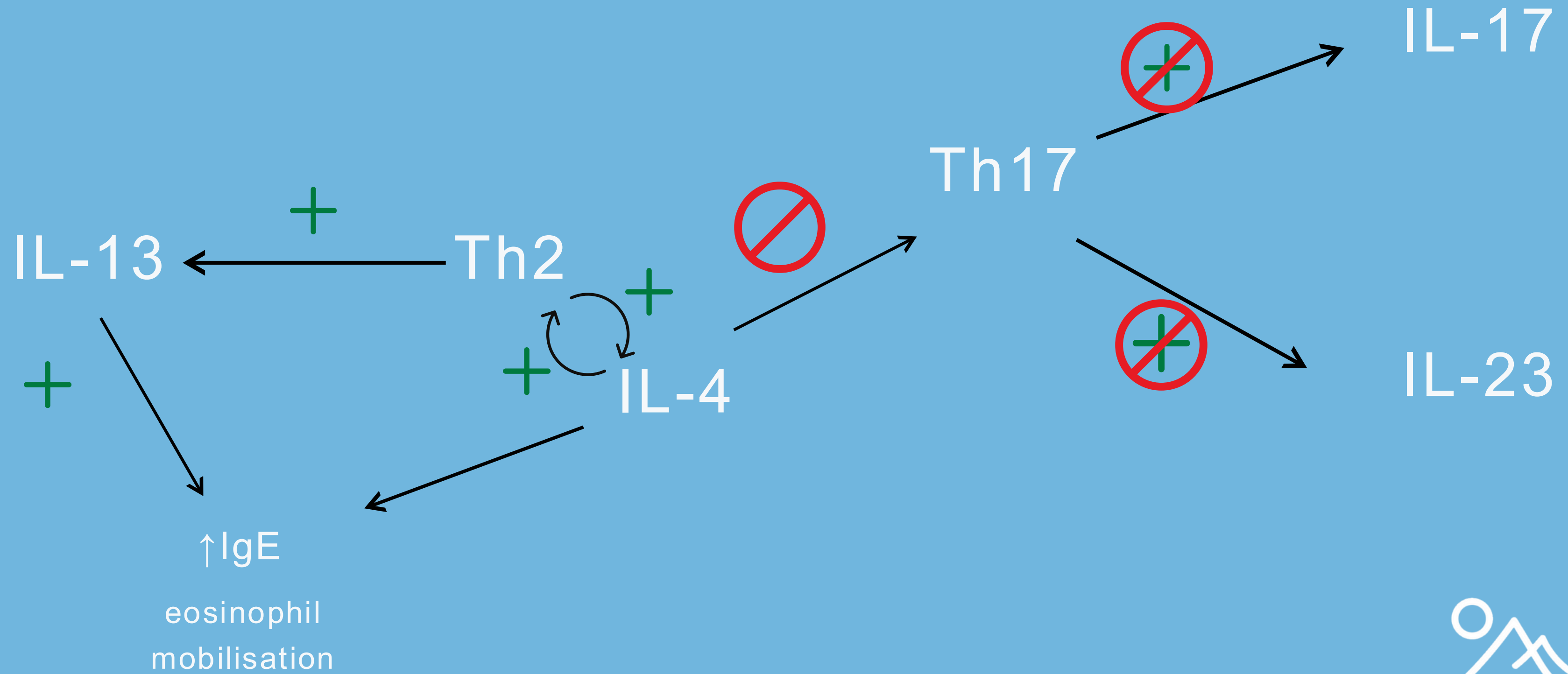
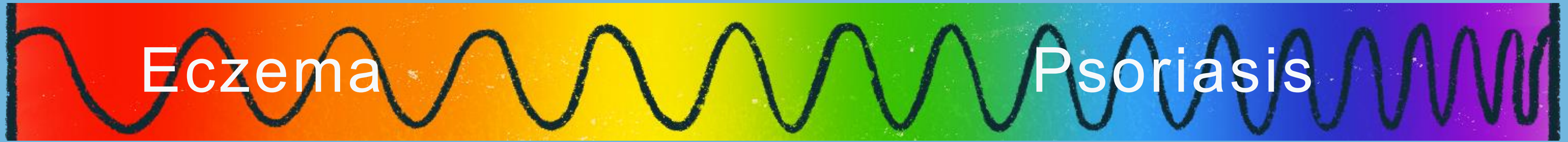
# Nummular dermatitis (discoïd eczema)

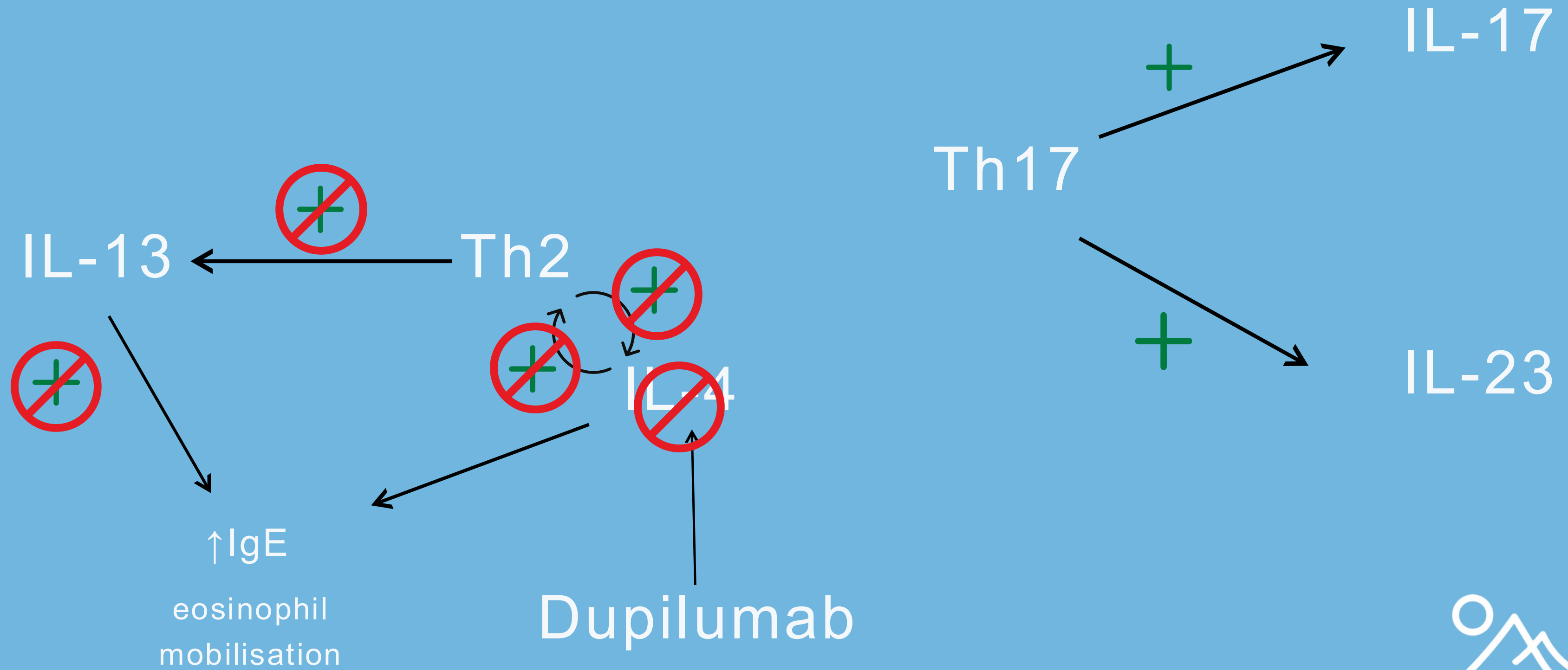
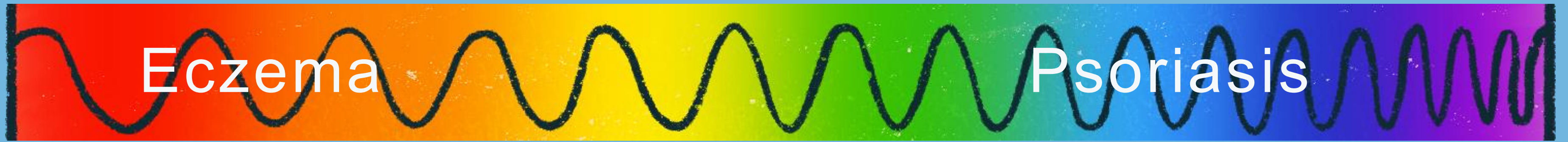
- Widely accepted as a variant of AD (Type 2 inflammatory response) (1)
- Features overlap with psoriasis (Type 1 inflammatory response) (1)

Nummular dermatitis	Type 2 features	Type 1 features
Impaired skin barrier	✓	
High levels of IL4 and IL 13 infiltrates compared to IL17	✓	
Spongiosis and eosinophilic infiltrates on histology	✓	
Upregulation of IL13, GATA3, CCL17, CCL18, CCL26, and CCL27	✓	
Normal IgE levels	✓	
Acanthosis and parakeratosis		✓
Expression of CXCL5, IL23A, and IL17F		✓
Neutrophil infiltration		✓

Table 1: Features of nummular dermatitis, Based on Böhner A, Jargosch M, Müller NS, Garzorz-Stark N, Pilz C, Lauffer F, et al. The neglected twin: Nummular eczema is a variant of atopic dermatitis with codominant TH2/TH17 immune response. Journal of Allergy and Clinical Immunology. 2023;152(2):408–19. doi: 10.1016/j.jaci.2023.04.009









# Nummular dermatitis variant

- The development of nummular dermatitis in response to dupilumab challenges our understanding the condition.
- Behaves like a variant of psoriasis.
- **?Two immunologically distinct variants of ND**
  - •Eczema variant (Th2-dominant) responds to dupilumab
  - Psoriasis variant (Th-17 dominant) associated with higher Th-17 activity, linked with new onset psoriasis.

# References

1. Böhner A, Jargosch M, Müller NS, Garzorz-Stark N, Pilz C, Lauffer F, et al. The neglected twin: Nummular eczema is a variant of atopic dermatitis with codominant TH2/TH17 immune response. *Journal of Allergy and Clinical Immunology*. 2023;152(2):408–19. doi: 10.1016/j.jaci.2023.04.009
2. Brumfiel CM, Patel MH, Zirwas MJ. Development of psoriasis during treatment with dupilumab: A systematic review. *J Am Acad Dermatol*. 2022;86(3):708–9. doi: 10.1016/j.jaad.2021.05.013
3. Barei F, Calzari P, Valtellini L, Chiei Gallo A, Perego G, Tavecchio S, et al. Five-year real-world drug survival of dupilumab in severe atopic dermatitis and associate predictors. *Journal of Dermatological Treatment*. 2024;35(1). doi: 10.1080/09546634.2024.2404718
4. Murphy MJ, Cohen JM, Vesely MD, Damsky W. Paradoxical eruptions to targeted therapies in dermatology: A systematic review and analysis. *J Am Acad Dermatol*. 2022;86(5):1080–91. doi: 10.1016/j.jaad.2020.12.010
5. Su Z, Zeng Y-P. Dupilumab-Associated Psoriasis and Psoriasiform Manifestations: A Scoping Review. *Dermatology*. 2023;239(4):646–57. doi: 10.1159/000530608
6. Tavecchio S, Angileri L, Pozzo Giuffrida F, Germiniasi F, Marzano AV, Ferrucci S. Efficacy of Dupilumab on Different Phenotypes of Atopic Dermatitis: One-Year Experience of 221 Patients. *J Clin Med*. 2020;9(9):2684. doi: 10.3390/jcm9092684
7. McCann MR, Kosloski MP, Xu C, Davis JD, Kamal MA. Dupilumab: Mechanism of action, clinical, and translational science. *Clin Transl Sci*. 2024;17(8). doi: 10.1111/cts.13899